

Efficacy of Crosseal Fibrin Sealant (Human) in Rhytidectomy

Samson Lee, MD; Annette M. Pham, MD; Shepherd G. Pryor, MD; Travis Tollefson, MD; Jonathan M. Sykes, MD

Objective: To examine the potential efficacy of Crosseal (the human protein, bovine component-free fibrin sealant) (OMRIX Biopharmaceuticals, Ltd, Brussels, Belgium) to reduce ecchymoses and hematoma formation in patients undergoing rhytidectomy.

Methods: Before initiation of the study, approval was obtained from the US Food and Drug Administration for an Investigational New Drug Application and off-label use of Crosseal and from the Institutional Review Board of the University of California, Davis. Patients undergoing rhytidectomy with or without concomitant procedures were voluntarily enrolled without compensation in the study (N=9). Patients were randomized according to which side of the rhytidectomy the tissue sealant was placed. In all patients in the study, 1 side of the rhytidectomy was treated with Crosseal; the other, untreated side was used as a control. Before closure of the skin, 2 mL of Crosseal was sprayed through a pressure regulator under the skin flap of the dissected area of the rhytidectomy only on 1 side. The skin was pretrimmed before placement and closed in standard fashion. A pressure dressing was left in place for 3 days before removal. Nine patients were originally enrolled in the study. On postoperative days 3 and 7, photographs were taken of the patients. The photographs were judged by 5 indepen-

dent reviewers who were blinded as to which side had been treated with Crosseal. The judges rated the degree of ecchymoses on a scale of 1 (minimal) to 10 (severe) and were asked their opinion as to which side of the face-lift had been treated with Crosseal. These results were compared using statistical analysis. Also on days 3 and 7, patients were examined for seroma or hematoma formation on each side of the face.

Results: Our study demonstrated efficacy of Crosseal in reducing ecchymoses and swelling in all patients. The mean score for ecchymosis on the Crosseal-treated side was 4.5 and on the untreated (control) side was 6.2 ($P < .01$, Wilcoxon rank sum test). The rate of hematoma or seroma formation was 22% (2 of 9 patients) for the untreated side vs 0% (0 of 9 patients) for the treated side. This did not reach statistical significance ($P = .43$, Fisher exact test). Small hematomas developed in 2 patients on the control side, which were needle aspirated. There were no known long-term complications from either the use of Crosseal or the rhytidectomy.

Conclusion: Crosseal is efficacious in reducing ecchymoses after rhytidectomy.

Arch Facial Plast Surg. 2009;11(1):29-33

HEMATOMA IS THE MOST common complication of rhytidectomy. Several studies of the incidence of hematoma in rhytidectomy have been published, with the rate of hematoma formation reported as 1.86% to 9.0%.¹⁻³ Depending on their size, hematomas may require only observation or aspiration or they may require operative intervention. Reducing the rate of hematoma formation has been a long-standing goal for many surgeons. Methods used to reduce hematoma formation may also reduce ecchymosis formation and, therefore, have the potential to shorten recovery time after rhytidectomy. With the increasing trend toward more minimally invasive procedures, the desire for shorter recovery time has been heightened.

Various techniques with the objective of reducing hematoma formation in-

clude use of drains^{4,5} and application of autologous platelet gel,⁶⁻⁹ among others. One of the more controversial methods of reducing hematoma formation is the use of fibrin sealant or tissue glue.^{1,2,10-16}

Fibrin sealant was first introduced in 1972 and was extensively used in Europe before being approved in 2003 for use in the United States. The basic components of fibrin glue consist of pooled purified plasma from human blood donors. The end result of the purification process is a liquid primarily consisting of fibrinogen. Fibrinogen is then combined with thrombin, either bovine or human, typically through an application device. Thrombin acts as a protease, cleaving fibrinogen to form fibrin, the basis for clot formation. Furthermore, thrombin activates factor XIII, which then cross-links fibrin to form a more stable clot. Many formulations of fibrin glue also contain an antifibrinolytic factor to reduce dis-

Author Affiliations:

Department of Otolaryngology, University of Miami, Miami, Florida (Dr Pham); and Division of Facial Plastic and Reconstructive Surgery, Department of Otolaryngology, University of California at Davis, Sacramento (Drs Tollefson and Sykes). Drs Lee and Pryor are in private practice in Bellevue, Washington, and Scottsdale, Arizona, respectively.

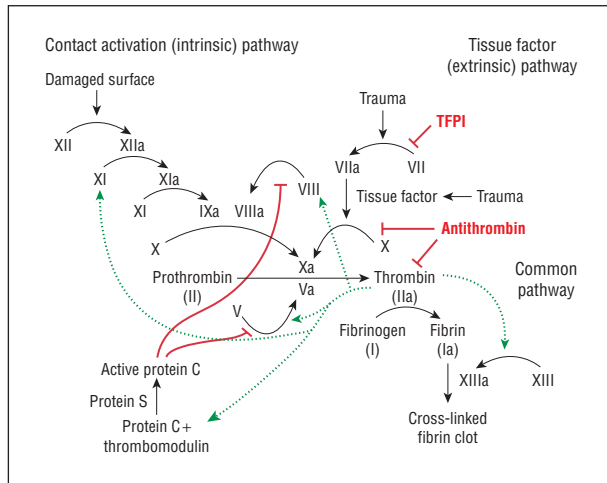


Figure 1. Coagulation cascade. TFPI indicates tissue factor pathway inhibitor.

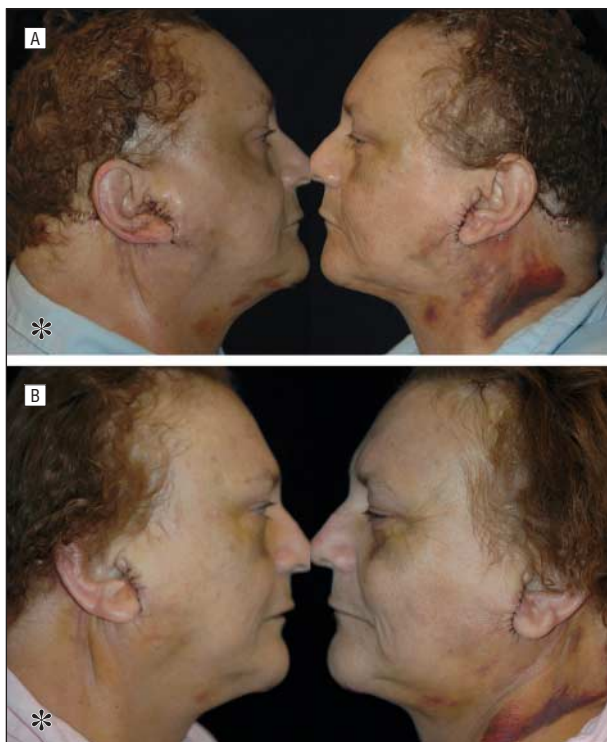


Figure 2. Photographs taken on postoperative days 3 (A) and 7 (B) after rhytidectomy. The left side of the patient's face was untreated; the right side was treated with Crosseal Fibrin Sealant (Human) (the human protein, bovine component-free fibrin sealant) (OMRIX Biopharmaceuticals, Ltd, Brussels, Belgium) as indicated by the asterisk.

solution of the fibrin clot (**Figure 1**). In a single-blinded, randomized, placebo-controlled, single-institution study, we examined the ability of a fibrin sealant, Crosseal Fibrin Sealant (Human) (the human protein, bovine component-free fibrin sealant) (OMRIX Biopharmaceuticals, Ltd, Brussels, Belgium), hereafter referred to as Crosseal, to reduce ecchymosis and hematoma formation in rhytidectomy.

METHODS

Nine individuals were enrolled in the study voluntarily by 2 of us (T.T. and J.M.S.). Before initiation of the study, approval was ob-

tained from the US Food and Drug Administration for Investigational New Drug Application and off-label use of Crosseal in rhytidectomy and from the Institutional Review Board of the University of California, Davis. All patients signed informed surgical written consent for both inclusion in the study and to undergo the procedure.

The patients were categorized by random drawing according to the side on which Crosseal was to be used. A double-blinded study could not be performed because the operating surgeon (T.T. or J.M.S.) knew which side of the rhytidectomy was treated with Crosseal. All patients in the study underwent a deep-plane rhytidectomy. Preoperative infiltration with lidocaine hydrochloride, 1%, with 1:100 000 epinephrine and lidocaine, 0.5%, with 1:200 000 epinephrine was performed in addition to tumescence with isotonic sodium chloride solution. Some patients underwent adjunctive procedures such as brow-lift, blepharoplasty, or fat augmentation in addition to rhytidectomy. In all patients in the study, 1 side of the rhytidectomy was treated with Crosseal and the other, untreated side, was used as a control.

After completion of elevation of the superficial musculoaponeurotic system and anchoring but before closure of the skin, 2 mL of Crosseal was sprayed through a pressure regulator under the skin flap of the dissected area of the rhytidectomy on only 1 side. The skin was pretrimmed before placement of Crosseal to prevent breaking up of the fibrin clot formation. The skin was closed in standard fashion. No drains are normally used and were not used in this study. A pressure dressing was left in place for 3 days before removal, as is customary for both operating surgeons (T.T. and J.M.S.).

On postoperative days 3 and 7, photographs were taken (**Figure 2** and **Figure 3**). Hematoma or seroma formation and the side on which they occurred were recorded. The photographs were rated by 5 independent reviewers who were blinded to the side to which Crosseal was applied. Ecchymosis was graded on a scale of 1 (minimal) to 10 (severe). The reviewers were also asked to choose to which side they thought the Crosseal might have been applied, judging by the degree of ecchymosis seen in the photograph. Only the area of the rhytidectomy to which the Crosseal was applied was examined; thus, the reviewers were asked to ignore bruising around the lips or eyes that may have occurred as a result of concurrent brow-lift, blepharoplasty, or fat augmentation. Standard Fisher exact and Wilcoxon rank sum tests were used to determine statistical significance.

RESULTS

No obvious adverse reactions were observed as a result of use of Crosseal. There was no obvious long-term asymmetry in rhytidectomy results or known allergic reaction from use of Crosseal.

All 5 independent reviewers correctly identified the side on which Crosseal was used except in 1 patient at day 3 when the reviewers did not reach consensus. However, on day 7, all reviewers correctly identified the correct side on which Crosseal was used in this patient, in whom a small seroma had developed on the untreated side that became apparent on day 7 (**Figure 2B**).

The mean score for ecchymosis on the Crosseal-treated side was 4.5; for the untreated or placebo-controlled side it was 6.2 ($P < .01$, Wilcoxon rank sum test). The rate of hematoma or seroma formation was 22% (2 of 9 patients) for the untreated side vs 0% (0 of 9 patients) for the treated side. This did not reach statistical significance ($P = .43$, Fisher exact test). Hematomas in both patients were small and easily evacuated using aspira-

tion and followed by an application of a continued pressure dressing. No long-term sequelae were noted from these hematomas other than delayed recovery time.

COMMENT

Fibrin sealants have been used in many types of surgical procedures. Fibrin sealant was first introduced in 1972 in Europe and used there extensively before its introduction in the United States. The rate of recorded adverse reactions secondary to fibrin glue was extremely low in Europe. These adverse outcomes consisted of mild to severe allergic reactions to the bovine products sometimes used in certain formulations of fibrin glue. This bovine component usually consists of the antifibrinolytic compound aprotinin, but some formulations of fibrin sealant use bovine thrombin as well. The rate of possible allergic reaction to bovine products from tissue sealant is thought to range from 0.3 (mild) to 0.5 (severe) per 100 000 uses. Multiple severe adverse reactions to aprotinin used both by itself and in fibrin glue have been reported.¹⁷⁻²⁵ There is a theoretical risk of viral and prion transmission from use of fibrin sealants because it is pooled from human plasma; however, no documented cases in millions of applications of fibrin sealant have been reported.

Tisseel Fibrin Sealant (a pooled component of human plasma that contains primarily fibrinogen with extraneous addition of human thrombin) (Baxter International Inc, Deerfield, Illinois), hereafter referred to as Tisseel, is the most commonly used fibrin sealant available in the United States and was first approved by the US Food and Drug Administration in 2000. Tisseel does use a bovine component of aprotinin as its antifibrinolytic factor. It is safe to use in neurosurgical applications.

Crosseal was first approved by the US Food and Drug Administration in 2003 as an adjunct to hemostasis in patients undergoing liver surgery. It differs from Tisseel in that it does not contain a bovine component and, thus, carries no risk of allergic reaction to bovine products. This is because it uses tranexamic acid as its antifibrinolytic compound rather than the bovine-derived aprotinin.²⁶ Crosseal is easier to reconstitute because, unlike Tisseel, it does not require premixing. Crosseal has a distinct disadvantage in that it cannot be used in neurosurgical applications because tranexamic acid can cause a potentially severe adverse reaction when in contact with brain tissue, dura mater, or cerebrospinal fluid.

Crosseal has recently been discontinued and reformulated as Evicel Fibrin Sealant (Human) (only all-human plasma-derived fibrin sealant without tranexamic acid) (OMRIX Biopharmaceuticals, Ltd), hereafter referred to as Evicel, for US Food and Drug Administration–approved use in liver, peripheral vascular, and general surgical applications. Evicel contains the same components as Crosseal and is, thus, no longer contraindicated for use in neurosurgical applications. Evicel maintains effectiveness in reducing bleeding in liver and peripheral vascular surgery despite the lack of the antifibrinolytic factor tranexamic acid. Evicel can be reconstituted in less than 1 minute and requires no premixing.

Several studies have examined the effectiveness of fibrin sealants in reducing hematoma and ecchymosis for-

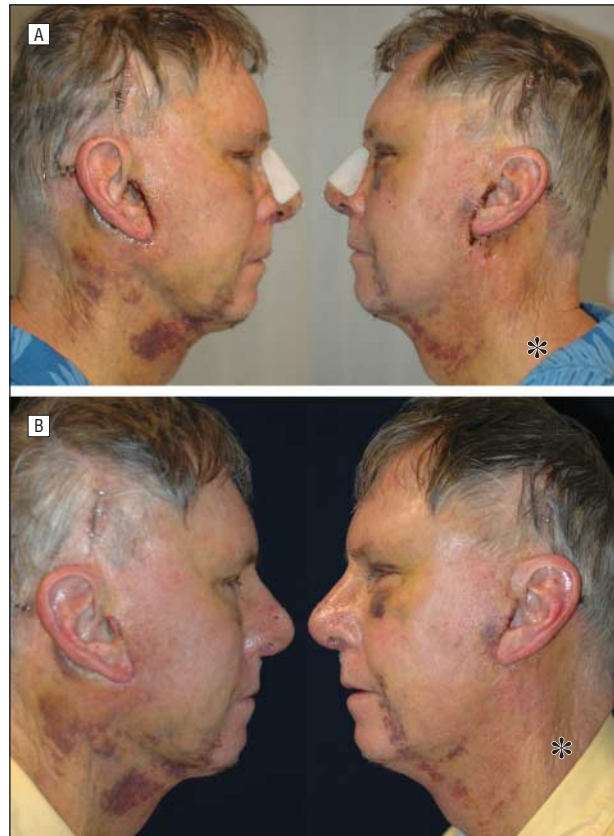

Figure 3. Photographs taken on postoperative days 3 (A) and 7 (B) after rhytidectomy. The left side of the patient's face was treated with Crosseal Fibrin Sealant (Human) (the human protein, bovine component–free fibrin sealant) (OMRIX Biopharmaceuticals, Ltd, Brussels, Belgium) as indicated by the asterisk; the right side was untreated.

Table. Reduction of Ecchymosis and Hematoma With Use of Fibrin Sealants in Rhytidectomy

Source	Reduced Ecchymosis	Reduced Hematoma	No. of Patients
Marchac and Sándor ²	Yes (statistically significant)	9% to 2%	100 of 200
Grover et al ²⁷	Not reported	No difference	410 of 1078
Jones et al ⁴	Not reported	No difference	412 of 641
Oliver et al ¹⁶	Not reported	No difference	20 (Patients served as own control)
Kamer and Nguyen ²⁸	From 22% to 0% (statistically significant)	No difference	100 of 200
Grossman et al ²⁹	Reported	Reported	200
Fezza et al ¹¹	Yes (statistically significant)	8.3% to 0% (trend, but not statistically significant)	24 of 48
Marchac and Greensmith ¹⁴	No change	No change	30 (Patients served as own control)

mation in rhytidectomy (**Table**). By reducing the rate of hematoma and ecchymosis formation, recovery time can be shortened. There have been anecdotal reports of the effectiveness of fibrin glue in rhytidectomy.^{10,29} Grover

et al²⁷ found no difference in hematoma formation in 410 patients treated with fibrin sealant. They found that the only factors that substantially affect hematoma formation are male sex, recent history of smoking, anterior platysmaplasty, preoperative hypertension, and use of aspirin or nonsteroidal anti-inflammatory drugs.²⁷

Marchac and Sándor² conducted a study that showed that fibrin glue reduced the rate of hematoma formation and ecchymosis in 100 patients. Hematoma formation was reduced from 9% to 2% with the use of fibrin sealant.² Marchac and Greensmith¹⁴ published a follow-up prospective, randomized, placebo-controlled study that showed that fibrin sealant may not have been as efficacious as was originally thought. They found no difference in hematoma or ecchymosis formation with the use of fibrin sealant. They did find an appreciable decrease in drainage from surgical drains with use of fibrin sealant; however, this was not clinically significant.¹⁴

Jones and Grover¹ showed no reduction in hematoma formation with the application of fibrin sealant in 412 patients. In addition, they found no significant reduction in hematoma formation with drains, pressure dressings, or use of tumescence. They did find a significant increase in the incidence of hematoma formation when epinephrine therapy was not used.

Oliver et al¹⁶ conducted a placebo-controlled, randomized study similar to ours in that 1 side of the rhytidectomy was treated with fibrin sealant and the other side was not. In 20 patients, they showed no significant difference in hematoma formation but did show decreased drainage output on the side treated with fibrin sealant. They did not report whether ecchymosis formation was reduced with use of fibrin sealant.

Fezza et al¹¹ showed a trend toward decreased hematoma formation with use of fibrin sealant, although this was not statistically significant. They did show a significant decrease in ecchymosis formation with use of fibrin sealant.¹¹

Kamer and Nguyen,²⁸ in a series of 200 patients, showed a reduction in swelling, ecchymosis, and induration with use of fibrin sealant. Their study did not show a statistically significant difference in hematoma or seroma formation, although it did show a trend toward reduction in hematoma and seroma formation.²⁸ Application of the fibrin sealant is important in that a thin coat should be sprayed on all areas that have been dissected. Care must also be taken to minimally lift the skin flap after application of the fibrin sealant.

The main disadvantage of use of fibrin sealant is cost, usually several hundred dollars for a few milliliters of glue. To our knowledge, no studies have examined the cost-benefit ratio of fibrin sealant use. Fibrin sealant that contains a bovine component can rarely cause potentially adverse allergic reactions. Even fibrin sealant formulations that do not contain bovine components can potentially result in an allergic reaction in an individual who may be sensitive to blood products. In addition, there is a theoretical risk of viral or prion transmission with the use of fibrin glue.

Our results show that Crosseal can reduce ecchymosis ($P=.007$, Wilcoxon rank sum test) and hematoma formation ($P=.43$ for trend, Fisher exact test) and, thus, shorten recovery time after rhytidectomy. The strength of the study

is that it was a prospective, randomized, placebo-controlled study, in contrast to some other studies that did not have adequate controls. There are many important limitations to the present study. The number of patients is small and, thus, it is difficult to definitively draw any conclusions about Crosseal and its use in rhytidectomy, particularly its ability to reduce hematoma formation. Patients did have some trepidation that the result on 1 side may be compromised despite reassurance that this was highly unlikely. As part of the process of informed surgical consent, patients were made aware of the theoretical risk of blood product allergy and infectious disease transmission. This led some patients to choose not to participate in the study despite reassurances.

Other drawbacks of the study were that there was more than 1 operating surgeon; thus, slight variances in technique may have affected outcome. Additional ancillary procedures were also performed. Reviewers were asked not to include these areas (eg, lips or eyes) in their analysis; however, they may have been affected by it subjectively in examining the photographs. Although unlikely, blood may have tracked from these areas into the dissection plane area of the rhytidectomy, possibly affecting results. Also, grading of ecchymosis is subjective.

CONCLUSIONS

From this small single-blinded, randomized, placebo-controlled, single-institution study, we can conclude that Crosseal is safe to use without any adverse outcomes. Use of Crosseal enabled a significant reduction in ecchymosis formation and showed a trend toward reducing hematoma formation; thus, Crosseal has the potential to shorten recovery time after rhytidectomy. Fibrin glue is a useful adjunct to rhytidectomy; however, the costs must be weighed against the benefits. Perhaps using Crosseal in mini-face-lifts or similar procedures is worthwhile because of the patient's perception that these procedures result in less bruising.

Accepted for Publication: March 7, 2008.

Correspondence: Samson Lee, MD, Lake Washington Facial Plastic Surgery, 1135 116th Ave NE, Ste 500, Bellevue, WA 98004 (samsonjlee@yahoo.com).

Author Contributions: Dr Sykes had full access to all of the data in the study and takes responsibility for the integrity of the data and the accuracy of the data analysis. *Study concept and design:* Lee, Tollefson, and Sykes. *Acquisition of data:* Lee, Pryor, Tollefson, and Sykes. *Analysis and interpretation of data:* Lee. *Drafting of the manuscript for important intellectual content:* Lee, Pryor, and Sykes. *Statistical analysis:* Lee. *Obtained funding:* Lee. *Administrative, technical, and material support:* Lee, Pham, and Sykes. *Study supervision:* Lee and Sykes.

Financial Disclosure: None reported.

Funding/Support: Johnson & Johnson provided Crosseal to the patients at no cost.

Role of the Sponsor: Johnson & Johnson had no role in the design and conduct of the study; collection, management, analysis, and interpretation of the data; or preparation, review, or approval of the manuscript.

Previous Presentation: This study was presented at the fall meeting of the American Academy of Facial Plastic and Reconstructive Surgery; September 20, 2007; Washington, DC.

REFERENCES

1. Jones BM, Grover R. Avoiding hematoma in cervicofacial rhytidectomy: a personal 8-year quest; reviewing 910 patients. *Plast Reconstr Surg.* 2004;113(1):381-390.
2. Marchac D, Sándor G. Face lifts and sprayed fibrin glue: an outcome analysis of 200 patients. *Br J Plast Surg.* 1994;47(5):306-309.
3. Rees TD, Barone CM, Valauri FA, Ginsberg GD, Nolan WB III. Hematomas requiring surgical evacuation following face lift surgery. *Plast Reconstr Surg.* 1994;93(6):1185-1190.
4. Jones BM, Grover R, Hamilton S. The efficacy of surgical drainage in cervicofacial rhytidectomy: a prospective, randomized, controlled trial. *Plast Reconstr Surg.* 2007;120(1):263-270.
5. Perkins SW, Williams JD, Macdonald K, Robinson EB. Prevention of seromas and hematomas after face-lift surgery with the use of postoperative vacuum drains. *Arch Otolaryngol Head Neck Surg.* 1997;123(7):743-745.
6. Brown SA, Appelt EA, Lipschitz A, Sorokin ES, Rohrich RJ. Platelet gel sealant use in rhytidectomy. *Plast Reconstr Surg.* 2006;118(4):1019-1025.
7. Chajchir A. Platelet gel sealant use in rhytidectomy [comment]. *Plast Reconstr Surg.* 2007;120(3):809.
8. Kent KJ. Promising results from a preliminary study of autologous platelet gel in face-lift surgery [comment]. *Arch Facial Plast Surg.* 2001;3(4):251.
9. Powell DM, Chang E, Farrior EH. Recovery from deep-plane rhytidectomy following unilateral wound treatment with autologous platelet gel: a pilot study. *Arch Facial Plast Surg.* 2001;3(4):245-250.
10. Baxt S. Tissue glue. *Plast Reconstr Surg.* 2001;107(5):1311-1312.
11. Fezza JP, Cartwright M, Mack W, Flaharty P. The use of aerosolized fibrin glue in face-lift surgery. *Plast Reconstr Surg.* 2002;110(2):658-666.
12. Flemming I. Fibrin glue in face lifts. *Facial Plast Surg.* 1992;8(1):79-88.
13. Jones BM, Grover R. Early postoperative efficacy of fibrin glue in face lifts: a prospective randomized trial. *Plast Reconstr Surg.* 2007;119(1):433-434.
14. Marchac D, Greensmith AL. Early postoperative efficacy of fibrin glue in face lifts: a prospective randomized trial. *Plast Reconstr Surg.* 2005;115(3):911-918.
15. Matarasso A, Rizk SS, Markowitz J. Short scar face-lift with the use of fibrin sealant. *Dermatol Clin.* 2005;23(3):495-504. vii.
16. Oliver DW, Hamilton SA, Figle AA, Wood SH, Lamberty BG. A prospective, randomized, double-blind trial of the use of fibrin sealant for face lifts. *Plast Reconstr Surg.* 2001;108(7):2101-2107.
17. Almodóvar LF, Lima P, Cañas A, Calleja M. Fatal anaphylactoid reaction after primary exposure to aprotinin. *Interact Cardiovasc Thorac Surg.* 2006;5(1):25-26.
18. Beierlein W, Scheule AM, Dietrich W, Ziemer G. Forty years of clinical aprotinin use: a review of 124 hypersensitivity reactions. *Ann Thorac Surg.* 2005;79(2):741-748.
19. Berguer R, Staerckel RL, Moore EE, Moore FA, Galloway WB, Mockus MB. Warning: fatal reaction to the use of fibrin glue in deep hepatic wounds: case reports. *J Trauma.* 1991;31(3):408-411.
20. Kon NF, Masumo H, Nakajima S, Tozawa R, Kimura M, Maeda S. Anaphylactic reaction to aprotinin following topical use of biological tissue sealant [in Japanese]. *Masui.* 1994;43(10):1606-1610.
21. Milde LN. An anaphylactic reaction to fibrin glue. *Anesth Analg.* 1989;69(5):684-686.
22. Mitsuhashi H, Horiguchi Y, Saitoh J, et al. An anaphylactic reaction to topical fibrin glue. *Anesthesiology.* 1994;81(4):1074-1077.
23. Orsel I, Guillaume A, Feiss P. Anaphylactic shock caused by fibrin glue [in French]. *Ann Fr Anesth Reanim.* 1997;16(3):292-293.
24. Scheule AM, Beierlein W, Lorenz H, Ziemer G. Repeated anaphylactic reactions to aprotinin in fibrin sealant. *Gastrointest Endosc.* 1998;48(1):83-85.
25. Scheule AM, Beierlein W, Wendel HP, Eckstein FS, Heinemann MK, Ziemer G. Fibrin sealant, aprotinin, and immune response in children undergoing operations for congenital heart disease. *J Thorac Cardiovasc Surg.* 1998;115(4):883-889.
26. Schwartz M, Madariaga J, Hirose R, et al. Comparison of a new fibrin sealant with standard topical hemostatic agents. *Arch Surg.* 2004;139(11):1148-1154.
27. Grover R, Jones BM, Waterhouse N. The prevention of haematoma following rhytidectomy: a review of 1078 consecutive facelifts. *Br J Plast Surg.* 2001;54(6):481-486.
28. Kamer FM, Nguyen DB. Experience with fibrin glue in rhytidectomy. *Plast Reconstr Surg.* 2007;120(4):1045-1052.
29. Grossman JA, Capraro PA, Atagi T. A prospective, randomized, double-blind trial of the use of fibrin sealant for face lifts. *Plast Reconstr Surg.* 2002;110(5):1371-1372.

Announcement

Visit www.archfacial.com. As an individual subscriber to Archives of Facial Plastic Surgery, you have to full-text online access to the journal from 1999 forward. In addition, you can find abstracts to all *JAMA & Archives Journals* as far back as 1975.